Video game ventricular tachycardia: The "Fortnite" phenomenon

Dustin Nash, MD, Hae-Rhi Lee, MD, Christopher Janson, MD, Chalese Richardson-Olivier, MD, Maully J. Shah, MBBS, FHRS

From The Cardiac Center, Department of Pediatrics, The Children's Hospital of Philadelphia, Philadelphia, Pennsylvania.

Introduction

Recommendations for the management of patients with certain arrhythmogenic cardiac conditions include restriction from strenuous activities and competitive sports.[1] Emotional stress has also been demonstrated as a trigger for arrhythmias in susceptible individuals.[2] Currently, there are no guidelines for engaging in nonphysical adrenergic activities. We present 2 cases of syncope and documented life-threatening ventricular tachycardia associated with strong emotional responses related to video war games.

Case report

Case 1

A 9-year-old otherwise healthy boy was evaluated for syncope, which occurred while he was playing the Fortnite Battle Royale game (Epic Games Inc, Cary, NC), a popular first-person-shooter online video game where up to 100 players fight to be the last person standing. During participation online in the game the patient was 1 of final 2 characters alive. After his character was eliminated he became very upset and lost consciousness. His father, who was participating in the same game from a different room, heard a noise through his headset as the child hit the floor and ran to his side, where he found the child to be cyanotic and rigid before spontaneously regaining consciousness within approximately 1 minute. Emergency medical services transported the boy to a local emergency room, where he had a normal physical examination and evaluation with normal serum chemistry and normal electrocardiogram, echocardiogram, and electroencephalogram.

A follow-up ambulatory Holter monitor demonstrated complex ventricular ectopy with multiple runs of polymorphic ventricular tachycardia. The densest period of ventricular tachycardia occurred during periods marked on the monitor as "playing video games," followed by "playing football" (Figure 1A–C).

The clinical diagnosis is catecholaminergic polymorphic ventricular tachycardia (CPVT), which is known to be associated with syncope and/or cardiac arrest triggered by physical or emotional stress.[1] In CPVT, variants in the human cardiac ryanodine receptor (*RyR2*) gene or calsequestrin 2 gene (*CASQ2*) result in abnormal intracellular Ca2+ regulation and induce arrhythmogenesis, particularly during β-adrenergic stimulation.[3] This patient was not known to have any type of cardiac condition, and syncope during video gaming unmasked the diagnosis. As shown in Figure 1A–C, ventricular arrhythmias were triggered during video gaming as well as recreational play, both activities that exert significant adrenergic influences. Further evaluation of the patient with an exercise test also demonstrated polymorphic ventricular tachycardia (VT) with increasing heart rate during exercise, similar to that shown while playing football on the ambulatory Holter monitor tracing (Figure 1C). Commercial genetic testing (GeneDx, Gaithersburg, MD) revealed what the company classified as a variant of unknown significance

KEY TEACHING POINTS

- Syncope associated with exercise and strong emotional response raises suspicion for an adrenergic-mediated tachycardia.
- In a small subset of children with underlying arrhythmogenic conditions, the adrenergic stimulation associated with the powerful emotions of electronic gaming may trigger life-threatening arrhythmias.
- Similar to exertional syncope, cardiac symptoms such as syncope or palpitations brought on by powerful emotions during video gaming should be a "red flag" prompting medical evaluation to rule out an underlying risk of arrhythmia.

KEYWORDS Ventricular tachycardia; Video games; Catecholaminergic polymorphic ventricular tachycardia; Adrenergic-mediated tachycardia; Sports participation

(Heart Rhythm Case Reports 2020;6:313–317)

Address reprint requests and correspondence: Dr Dustin Nash, The Cardiac Center, Department of Pediatrics, The Children's Hospital of Philadelphia, 3401 Civic Center Blvd, Philadelphia, PA 19104. E-mail address: nashdb@email.chop.edu.

2214-0271/© 2020 Heart Rhythm Society. Published by Elsevier Inc. This is an open access article under the CC BY-NC-ND license (http://creativecommons.org/licenses/by-nc-nd/4.0/).

https://doi.org/10.1016/j.hrcr.2020.02.007

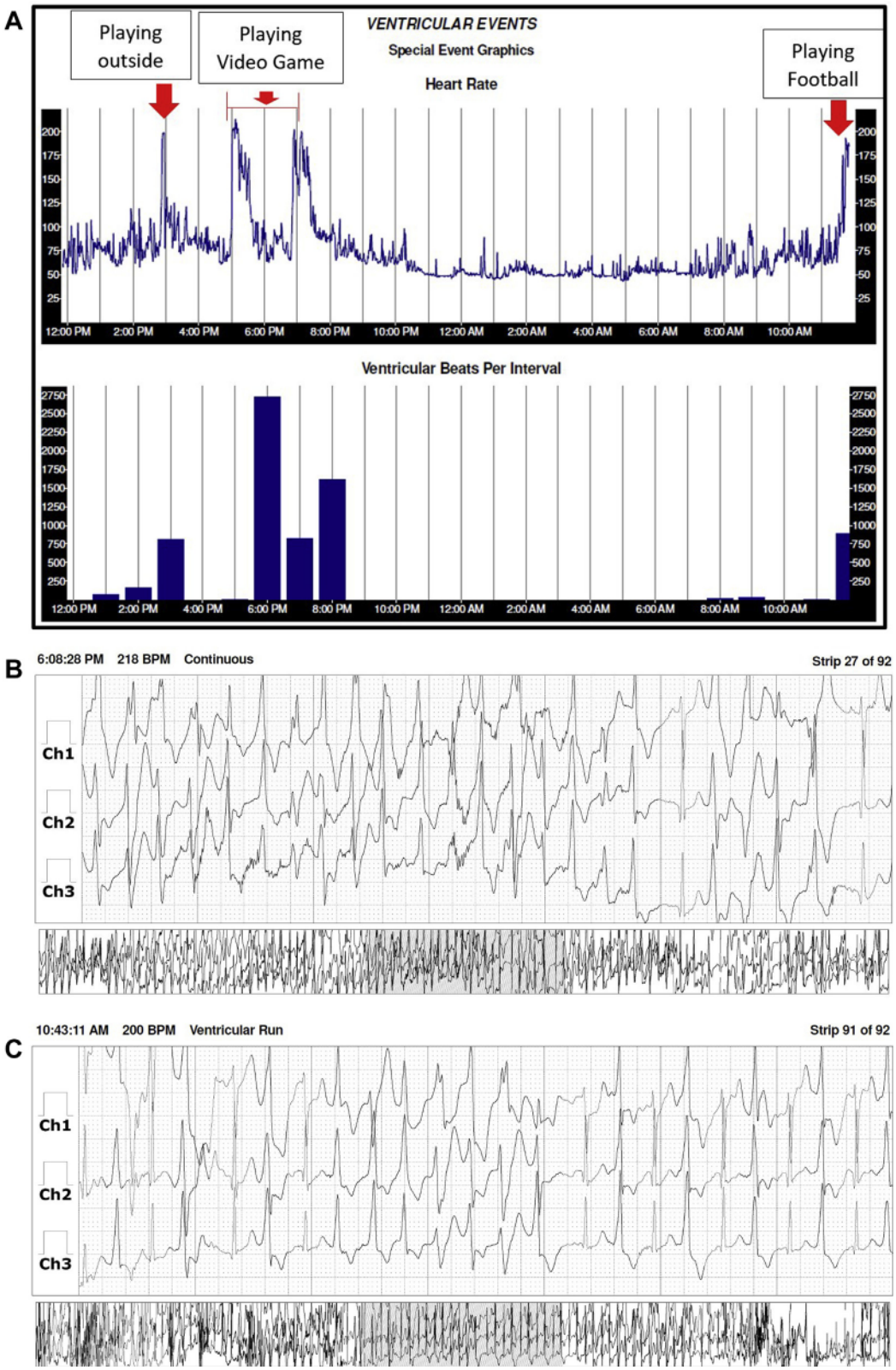

Figure 1 **A:** Graphic trends of ventricular events during 24-hour ambulatory Holter monitoring in case 1 shows increased heart rates (top panel) during the 3 patient notations of (1) playing outside, (2) playing video games, and (3) playing football. During the same periods of time, the histogram (bottom panel) shows increased density of ventricular beats per interval. In the top panel the y-axis shows heart rate (beats per minute [BPM]) and the x-axis shows time of day/night. In the bottom panel the y-axis shows ventricular beats per time interval and the x-axis shows time of day/night. **B:** Three-channel 24-hour ambulatory Holter monitoring shows continuous polymorphic ventricular tachycardia at 200–230 BPM in case 1 during playing of the Fortnite video game. **C:** Three-channel 24-hour ambulatory Holter monitoring shows a run of nonsustained ventricular tachycardia at 200–220 BPM followed by ventricular bigeminy in case 1 at the time of playing recreational football.

Figure 2 Remote monitoring in case 2 shows continuous recording of intracardiac electrograms from the patient's implantable cardioverter-defibrillator (ICD; Visia AF MRI VR SureScan, Medtronic Inc, Minneapolis, MN). Ventricular ectopy is followed by monomorphic ventricular tachycardia (VT) at a cycle length of 220–270 ms (222–270 beats/min) at the time of playing Fortnite followed by an ICD shock. The top channel shows right ventricle (RV)-tip-to-RV-ring electrograms and bottom channel shows can-to-RV-coil electrograms. The programmed ventricular fibrillation detection was 260 ms. Note that VT terminated spontaneously but a defibrillation shock was delivered due to the "Confirmation+" algorithm (nominally programmed to "on"), which prevented cancellation of therapy. Note that the VT electrogram morphology is different from sinus rhythm.

(VUS) in the *RYR2* gene (p.Ile4152Leu, c.12454 A>C in exon 90). This particular variant has not been previously published as pathogenic or benign, to our knowledge and based on our review of literature. It has also not been observed in large population cohorts.[4] This variant is located in domain III of the *RYR2* gene, one of the hot-spot regions where the majority of the missense variants occur.[5] The parents were evaluated and both were found to have no clinical symptoms. Genotyping of the parents (Invitae Diagnostics, San Francisco, CA) did not detect the RYR2 variant in either individual. Based on the de novo occurrence and correlation with clinical CPVT phenotype, it is likely pathogenic. In addition,

a VUS in *KCNA5* (c.213_245del133:p.D72_P82Del in exon 1) was also reported and was also present in the patient's mother. This latter VUS has been reported in association with idiopathic atrial fibrillation, but was not present in gnomAD.[6]

The patient has been advised to avoid vigorous exercise and violent video games and is currently treated with nadolol and flecainide, a class Ic antiarrhythmic medication that has also been shown to have direct-blocking effect on the RyR2 channel.

Case 2

A 16-year-old previously healthy male subject presented to our hospital after an aborted cardiac arrest that occurred while he was walking after attending music class in school. After resuscitation with an automatic external defibrillator (AED), the patient was brought to our emergency room, where he had a normal electrocardiogram, serum chemistry, echocardiogram, cardiac magnetic resonance imaging, and exercise stress test and a negative toxicology screen. His evaluation also included genetic testing with a comprehensive arrhythmia and cardiomyopathy panel (Combined Cardiac Sequencing and Deletion/Duplication Panel, GeneDx, Gaithersburg, MD), which did not show any pathologic variants. A diagnosis of idiopathic ventricular fibrillation was made after exclusion of known cardiac, respiratory, metabolic, and toxicological etiologies. The patient was discharged home after implantation of a transvenous implantable cardioverter-defibrillator (ICD) for secondary prevention of sudden cardiac death. One week after discharge, while playing the video game Fortnite, he became very excited at an anticipated win and then experienced an ICD discharge. ICD interrogation demonstrated monomorphic VT at 260 beats per minute followed by a committed ICD shock (Figure 2). The patient was in sinus rhythm after the ICD shock, with no other hemodynamic sequelae. Subsequently, the patient was advised to avoid violent video game activity and treated with a β-blocker, with no further arrhythmias or ICD therapy over a follow-up period of 12 months.

Discussion

These 2 cases highlight potentially life-threatening ventricular arrhythmias provoked by emotional surges while playing violent video games. We add this report to a recent correspondence discussing the association with ventricular arrhythmias and video games.[7] This case report includes 2 distinct examples of documentation of the actual rhythm abnormality during electronic war games. This phenomenon occurred in both patients during periods of excitement, engagement, and/or frustration with the game. Electronic video games are deliberatively designed to offer powerful affective experiences, and players typically go through a range of emotional responses that include frustration, anxiety, fear, excitement, and joy. In review of the literature, Wang and colleagues[8] demonstrated a significant increase in heart rate and blood pressure among young boys playing video games; however, the magnitude was lower than observed during standard physical exercise. Other studies have demonstrated that the violent games have distinct effects on autonomic responses such as heart rate variability.[9]

We propose that only a very small group of children may possibly be at risk of arrhythmia during video gaming. These children are likely to have an underlying (previously known or unknown) cardiac arrhythmia disorder. Similar to exertional syncope, cardiac symptoms such as syncope or palpitations brought on by powerful emotions during video gaming should be a "red flag" prompting medical evaluation to rule out an underlying risk of arrhythmia. The risk of a dangerous arrhythmia during competitive sports or swimming is well known in patients with inherited cardiac channelopathies such as long QT syndrome and CPVT.[1] A similar mechanism may be occurring when children with arrhythmogenic conditions experience powerful emotions during particular phases of video gaming. While the exact mechanism triggering the arrhythmia may be varied, given that both patients in this report had different conditions, 1 common part of the pathway is likely related to the sympathetic nervous system and adrenergic stimulation. Studies of the effects of intense emotion and mental stress, known triggers for ventricular arrhythmias, have demonstrated a shortening of the ventricular action potential.[10]

Recent studies have evaluated the safety of sports in treated patients with long QT syndrome and CPVT, and in patients with ICDs, and guidelines have followed suit, allowing for individualized shared decision-making.[11-15] Key foundations to this approach are the clear cardiovascular and psychosocial benefits of exercise and sports, as well as the recommendation that safety plans be in place, including on-site AEDs. In contrast to exercise and sports, violent video games do not provide cardiovascular benefits; furthermore, they are most often played in physical isolation, without the safety net of bystanders and AEDs. For these reasons, counseling of specific at-risk populations should include avoidance of participation in violent video games, as these games are an activity with risk and without health or psychosocial benefit.

Conclusion

Electronic video games have assumed a prominent role in the daily activities of children and adolescents in the current era. In a small subset of children with underlying arrhythmogenic conditions, the adrenergic stimulation associated with the powerful emotions of electronic gaming may trigger life-threatening arrhythmias. Even in children not known to have a cardiac condition, syncope associated with emotional responses during violent video games should prompt cardiac evaluation.

References

1. Priori SG, Wilde AA, Horie M, et al. HRS/EHRA/APHRS expert consensus statement on the diagnosis and management of patients with inherited primary arrhythmia syndromes: document endorsed by HRS, EHRA, and APHRS in

May 2013 and by ACCF, AHA, PACES, and AEPC in June 2013. Heart Rhythm 2013;10:1932–1963.
2. Lampert R, Joska T, Burg MM, Batsford WP, Mcpherson CA, Jain D. Emotional and physical precipitants of ventricular arrhythmia. Circulation 2002;106:1800–1805.
3. Brette F. Calcium polymorphic ventricular tachycardia. A new name for CPVT? Cardiovasc Res 2010;87:10–11.
4. Lek M, Karczewski KJ, Minikel EV, et al. Analysis of protein-coding genetic variation in 60,706 humans. Nature 2016;536:285–291.
5. Priori SG, Chen SR. Inherited dysfunction of sarcoplasmic reticulum Ca2+ handling and arrhythmogenesis. Circ Res 2011;108:871–883.
6. Tian L, Liu G, Wang L, Zheng M, Li Y. KCNA5 gene polymorphism associate with idiopathic atrial fibrillation. Int J Clin Exp Med 2015;8:9890–9896.
7. Lawley CM, Skinner JR, Turner C. Syncope due to ventricular arrhythmia triggered by electronic gaming. N Engl J Med 2019;381:1180–1181.
8. Wang X, Perry AC. Metabolic and physiologic responses to video game play in 7- to 10-year-old boys. Arch Pediatr Adolesc Med 2006;160:411–415.
9. Ivarsson M, Anderson M, Akerstedt T, Lindblad F. Playing a violent television game affects heart rate variability. Acta Paediatr 2009;98:166–172.
10. Child N, Hanson B, Bishop M, et al. Effect of mental challenge induced by movie clips on action potential duration in normal human subjects independent of heart rate. Circ Arrhythm Electrophysiol 2014;7:518–523.
11. Aziz PF, Sweeten T, Vogel RL, Henderson J, Patel AR, Shah MJ. Sports participation in genotype positive children with long QT syndrome. JACC Clin Electrophysiol 2015;1:62–70.
12. Ostby SA, Bos JM, Owen HJ, Wackel PL, Cannon BC, Ackerman MJ. Competitive sports participation in patients with catecholaminergic polymorphic ventricular tachycardia: a single center's early experience. JACC Clin Electrophysiol 2016;2:253–262.
13. Lampert R, Olshansky B, Cannom D, et al. Safety of sports for athletes with implantable cardioverter-defibrillators: results of a prospective, multinational registry. Circulation 2013;127:2021–2030.
14. Saarel EV, Law I, Lampert RJ, et al. Safety of sports for young patients with implantable cardioverter-defibrillators. Circ Arrhythm Electrophysiol 2018;11:e006305.
15. Maron BJ, Udelson JE, Maron MS, et al; American Heart Association Electrocardiography and Arrhythmias Committee of Council on Clinical Cardiology, Council on Cardiovascular Disease in Young, Council on Cardiovascular and Stroke Nursing, Council on Functional Genomics and Translational Biology, and American College of Cardiology. Eligibility and Disqualification Recommendations for Competitive Athletes With Cardiovascular Abnormalities: Task Force 3: Hypertrophic Cardiomyopathy, Arrhythmogenic Right Ventricular Cardiomyopathy and Other Cardiomyopathies, and Myocarditis: A Scientific Statement From the American Heart Association and American College of Cardiology. Circulation 2015;132:e273–e280.